

## Ruptured Brain Aneurysm

### Overview

An aneurysm is a balloon-like bulge of an artery wall. As an aneurysm grows it puts pressure on nearby structures and may eventually rupture. A ruptured aneurysm releases blood into the subarachnoid space around the brain. A subarachnoid hemorrhage (SAH) is a life-threatening type of stroke. Treatment focuses on stopping the bleeding and repairing the aneurysm with clipping, coiling, or bypass.

### What is a ruptured aneurysm?

An aneurysm is a balloon-like bulge or weakening of an artery wall. (Similar to a balloon on the side of a garden hose.) As the bulge grows it becomes thinner and weaker. It can become so thin that the blood pressure within can cause it to leak or burst open. Aneurysms usually occur on larger blood vessels at the fork where an artery branches off. Types of aneurysms include (Fig. 1):

- **Saccular** - (most common, also called "berry") the aneurysm bulges from one side of the artery and has a distinct neck at its base.
- **Fusiform** - the aneurysm bulges in all directions and has no distinct neck.
- **Dissecting** - a tear in the inner wall of the artery allows blood to split the layers and pool; often caused by a traumatic injury.

Aneurysms are also classified by size:

- Small = less than 7 millimeters in diameter
- Medium = 7-12 millimeters
- Large = 13-24 millimeters (size of a dime)
- Giant = more than 25 millimeters (quarter size)

When an aneurysm bursts it releases blood into the subarachnoid space between the brain and the skull. This space is filled with cerebrospinal fluid (CSF) that bathes and cushions the brain. As blood spreads and clots, it irritates the lining of the brain and damages brain cells. At the same time, the area of brain that previously received oxygen-rich blood from the affected artery is now deprived of blood, resulting in a stroke. A subarachnoid hemorrhage (SAH) is life threatening with a 40% risk of death.

Enclosed within the rigid skull, clotted blood and fluid buildup increases pressure that can crush the brain against the bone or cause it to shift and

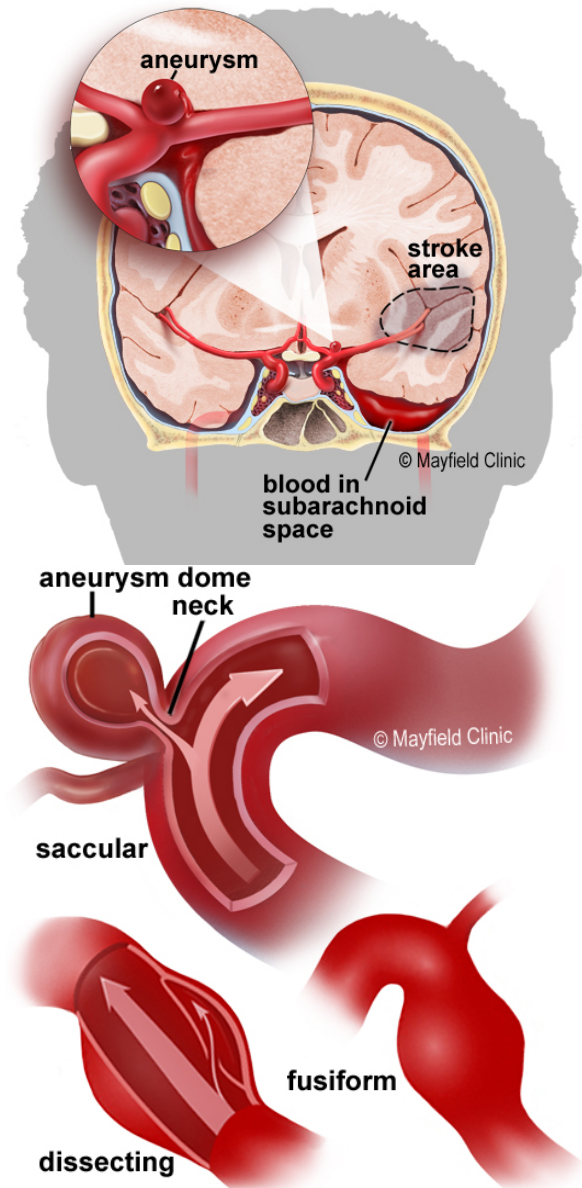


Figure 1. A ruptured aneurysm releases blood into the subarachnoid space around the brain causing a stroke (above). Different types of aneurysms (below).

herniate. Blockage of the normal CSF circulation can enlarge the ventricles (hydrocephalus) causing confusion, lethargy, and loss of consciousness.

A complication that may occur 5 to 10 days after aneurysm rupture is vasospasm (Fig. 2). Irritating blood byproducts cause the walls of an artery to spasm and narrow, reducing blood flow to that region of the brain and causing a secondary stroke.

### What are the symptoms?

Most aneurysms don't have symptoms until they rupture. Rupture usually occurs while a person is active rather than asleep. If you experience the symptoms of a SAH, call 911 immediately!

- Sudden onset of a severe headache (often described as "the worst headache of my life")
- Nausea and vomiting
- Stiff neck
- Sensitivity to light (photophobia)
- Blurred or double vision
- Loss of consciousness
- Seizures

### What are the causes?

Risk factors for aneurysm rupture include smoking, high blood pressure, drug or alcohol abuse, genetic (family inherited), atherosclerosis, and lifestyle habits.

### Who is affected?

About 2 to 3% of Americans may have or develop an aneurysm; of those, 15% have multiple aneurysms. Unruptured aneurysms are more common than ruptured. However, 85% of aneurysms are not diagnosed until after they bleed. Aneurysms are usually diagnosed between ages 35 to 60 and are more common in women.

### How is a diagnosis made?

When a person is brought to the emergency room with a suspected ruptured aneurysm, doctors will learn as much as possible about his or her symptoms, current and previous medical problems, medications, and family history. The person's condition is assessed quickly. Diagnostic tests will help determine the source of the bleeding.

- **Computed Tomography (CT)** scan is a noninvasive X-ray to review the anatomical structures within the brain and to detect blood in or around the brain (Fig 3). A CT angiography (CTA) involves the injection of contrast into the blood stream to view the arteries of the brain.
- **Lumbar puncture** is an invasive procedure in which a hollow needle is inserted in the low back to collect cerebrospinal fluid (CSF) from the spinal canal. The CSF is examined to detect blood from a suspected hemorrhage.
- **Angiogram** is an invasive procedure in which a catheter is inserted into an artery and passed through the blood vessels to the brain. Once the catheter is in place, contrast dye is injected into the bloodstream and x-rays are taken.
- **Magnetic Resonance Imaging (MRI)** scan is a noninvasive test that uses a magnetic field and radio-frequency waves to give a detailed view of the soft tissues of the brain. An MRA involves the injection of contrast into the blood stream to examine the blood vessels in addition to structures of the brain.

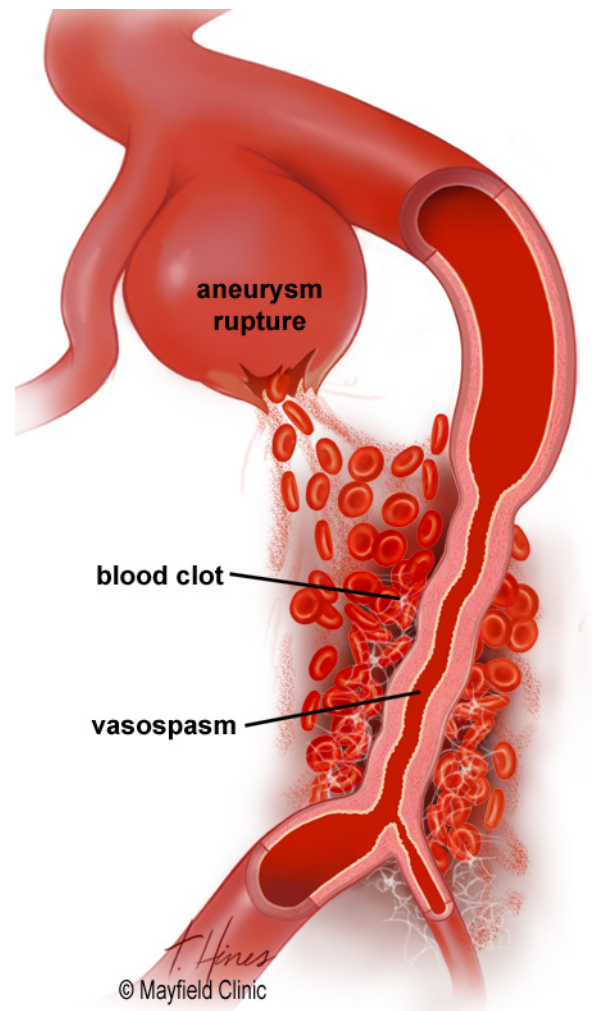


Figure 2. When red blood cells break down, toxins can cause the walls of nearby arteries to spasm and narrow. The larger the SAH, the higher the risk of vasospasm.

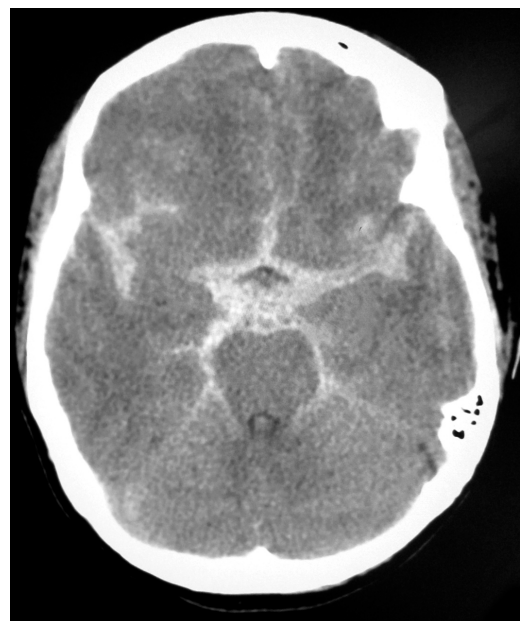

Figure 3. CT scan shows blood (white star-shape) in the subarachnoid space from a ruptured aneurysm.

Your loved one may be unable to make decisions about treatment. So you may need to decide what's best for him or her. The doctors may refer to the Hunt-Hess SAH scale as an indicator of the patient's condition.

Hunt-Hess scale grades:

- I Alert, no symptoms, mild headache or neck stiffness
- II Aware of surroundings, moderate to severe headache, stiff neck, no neurologic defect except cranial nerve palsy
- III Drowsy, weakness or partial or severe paralysis on one side of the body
- IV Dazed, total paralysis on one side of the body
- V Comatose, with abnormal posture

### What treatments are available?

Treatment may include lifesaving measures, symptom relief, repair of the bleeding aneurysm, and complication prevention. For 10 to 14 days following an aneurysm rupture, the patient will remain in the neuroscience intensive care unit (NSICU), where doctors and nurses can watch closely for signs of renewed bleeding, vasospasm, hydrocephalus, and other potential complications.

### Medication

Pain medication will be given to alleviate headache, and anticonvulsant medication may be given to prevent or treat seizures.

### Surgery

Determining the best treatment for a ruptured aneurysm involves many factors, such as the size and location of the aneurysm as well as how stable is the patient's current condition.

- **Surgical clipping:** an opening is cut in the skull, called a craniotomy, to locate the aneurysm. A small clip is placed across the "neck" of the aneurysm to block the normal blood flow from entering (Fig. 4). The clip is made of titanium and remains on the artery permanently.
- **Endovascular coiling:** is performed during an angiogram in the radiology department. A catheter is inserted into an artery in the groin and then passed through the blood vessels to the aneurysm in the brain. Through the catheter, the aneurysm is packed with platinum coils or glue, which prevents blood flow into the aneurysm (Fig. 5).
- **Artery occlusion and bypass:** if the aneurysm is large and inaccessible or the artery is too damaged, the surgeon may perform a bypass surgery. A craniotomy is cut to open the skull and clips are placed to completely block (occlude) the artery and aneurysm. The blood flow is then rerouted (bypassed) around the occluded artery by inserting a vessel graft. The

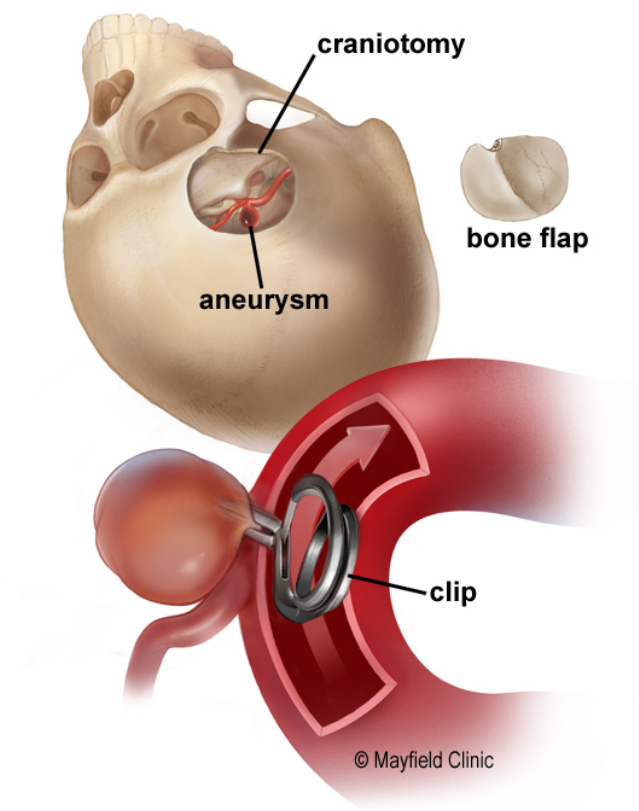


Figure 4. A titanium clip is placed across the neck of an aneurysm so that the blood flows through the artery (arrow), and not into the aneurysm.

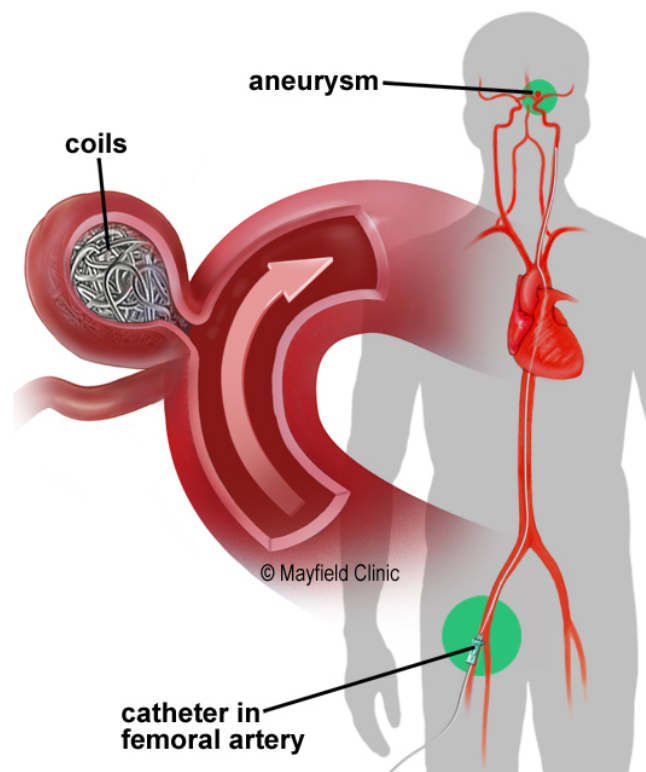


Figure 5. The aneurysm is packed with platinum coils. The coils induce clotting (embolization), which seals off the aneurysm and prevents blood from entering.



graft is a small artery, usually taken from your leg, which is connected above and below the blocked artery so that blood flows through the graft.

Another method is to detach a donor artery from its normal position on the scalp and connect it above the blocked artery inside the skull. This is called a STA-MCA (superficial temporal artery to middle cerebral artery) bypass.

### Controlling hydrocephalus

Clotted blood and fluid buildup in the subarachnoid space may cause hydrocephalus and elevated intracranial pressure. Blood pressure is lowered to reduce further bleeding and to control intracranial pressure. Excess cerebrospinal fluid (CSF) and blood may be removed with: 1) a lumbar drain catheter inserted into the subarachnoid space of the spinal canal in the low back, or 2) a ventricular drain catheter, which is inserted into the ventricles of the brain through a small hole in the skull.

### Controlling vasospasm

Five to 10 days after a SAH, the patient may develop vasospasm. Vasospasm narrows the artery and reduces blood flow to the region of the brain that the artery feeds. Vasospasm occurs in 70% of patients after SAH. Of these, 30% have symptoms that require treatment.

A patient in the NSICU will be closely monitored for signs of vasospasm, which include weakness in an arm or leg, confusion, sleepiness, or restlessness. Transcranial doppler (TCD) ultrasounds are performed routinely to monitor for vasospasm. TCDs are used to measure the blood flow through the arteries. This test can show which arteries are in spasm as well as the severity. To prevent vasospasm, patients are given the drug nimodipine while in the hospital. Additionally, the patient's blood pressure and blood volume will be increased to force blood through the narrowed arteries.

If vasospasm is severe, patients may require an injection of medication directly into the artery to relax and stop the spasm. This is done through a catheter during an angiogram. Sometimes balloon angioplasty is used to stretch open the artery.

### Clinical trials

Clinical trials are research studies in which new treatments—drugs, diagnostics, procedures, and other therapies—are tested in people to see if they are safe and effective. Research is always being

conducted to improve the standard of medical care. Information about current clinical trials, including eligibility, protocol, and locations, are found on the Web. Studies can be sponsored by the National Institutes of Health (see [www.clinicaltrials.gov](http://www.clinicaltrials.gov)) as well as private industry and pharmaceutical companies (see [www.centerwatch.com](http://www.centerwatch.com)).

### Recovery and prevention

The possibility of having a second bleed is 22% within the first 14 days after the first bleed. This is why neurosurgeons prefer to treat the aneurysm as soon as it is diagnosed, so that the risk of a rebleed is lessened.

Aneurysm patients may suffer short-term and/or long-term deficits as a result of a rupture or treatment. Some of these deficits may disappear over time with healing and therapy. After a patient is discharged from the hospital, treatment may be continued at a facility that offers personalized rehabilitation therapies following a serious brain injury. A doctor who specializes in rehabilitation will oversee this care, which can include physical, occupational, and speech therapy. The recovery process is long and may take months or years to understand the deficits you incurred and regain function.

### Sources & links

If you have more questions, please contact Mayfield Brain & Spine at 800-325-7787 or 513-221-1100.

#### Links

Brain Aneurysm Foundation  
[www.bafound.org](http://www.bafound.org) 617-723-3870

[www.brainaneurysm.com](http://www.brainaneurysm.com)

### Glossary

**aneurysm:** a bulge or weakening of an arterial wall.

**coiling:** a procedure to insert platinum coils into an aneurysm; performed during an angiogram.

**craniotomy:** surgical opening in the skull.

**embolization:** inserting material, coil or glue, into an aneurysm so blood can no longer flow through it.

**subarachnoid hemorrhage:** bleeding in the space surrounding the brain; may cause a stroke.

**vasospasm:** abnormal narrowing or constriction of arteries due to irritation by blood in the subarachnoid space.



updated > 1.2020

reviewed by > Andrew Ringer, MD and Craig Kilburg, MD, Mayfield Clinic, Cincinnati, Ohio

Mayfield Certified Health Info materials are written and developed by the Mayfield Clinic. We comply with the HONcode standard for trustworthy health information. This information is not intended to replace the medical advice of your health care provider. © Mayfield Clinic 1998-2020.