

Acoustic Neuroma (vestibular schwannoma)

Overview

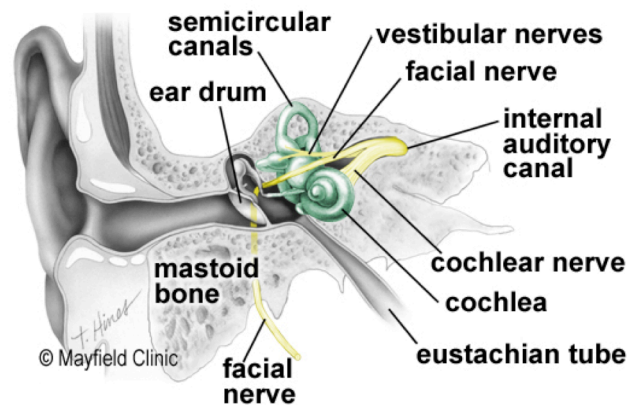
An acoustic neuroma is a tumor that grows from the nerves responsible for balance and hearing. These tumors grow from the sheath covering the vestibulocochlear nerve. Acoustic neuromas are benign (not cancer) and usually grow slowly. Over time the tumor can cause gradual hearing loss, ringing in the ear, and dizziness. Because of their slow growth, not all acoustic neuromas need to be treated. Treatment options include observation, surgery, and radiosurgery.

Anatomy of the ear

The ear is our organ of hearing and balance. It consists of three parts: the outer ear, the middle ear, and the inner ear. The middle and inner ear are located deep in the temporal bone of the skull. The vestibulocochlear nerve (eighth cranial nerve) is responsible for relaying hearing and balance signals from the inner ear to the brain.

The outer ear funnels sound down the ear canal to the eardrum, which vibrates three tiny bones called ossicles (malleus, incus, and stapes) in the middle ear (Fig. 1A). In turn, the stapes vibrates the oval window of the cochlea in the inner ear. The spiral-shaped cochlea is filled with liquid, which moves in response to vibrations. As the fluid moves, thousands of hair cells are stimulated, sending signals along the cochlear nerve, which are processed as hearing in the brain. Attached to the cochlea are three semicircular canals positioned at right angles to each other. The three canals are able to sense head position and body posture. Electrical signals from the semicircular canals are carried to the brain by the superior and inferior vestibular nerves (responsible for balance). The cochlear and vestibular nerves form a bundle inside the bony internal auditory canal before exiting to reach the brainstem. Inside the canal, the vestibulocochlear nerve lies next to the facial nerve. The facial nerve (seventh cranial nerve) is responsible for moving the muscles of the face. The close relationship of the vestibulocochlear and facial nerves explains why facial weakness can occur when an acoustic neuroma grows (Fig. 1B). Likewise, facial sensation and feeling is controlled by the trigeminal nerve (fifth cranial nerve) and can be affected by large tumors.

A. normal anatomy



B. acoustic neuroma

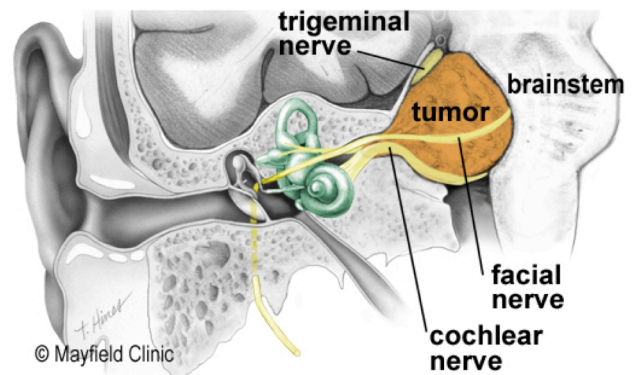


Figure 1A. The normal anatomy of the ear. B. An acoustic neuroma expands out of the internal auditory canal, displacing the cochlear, facial, and trigeminal nerves. Eventually, the tumor compresses the brainstem.

What is an acoustic neuroma?

An acoustic neuroma, also called vestibular schwannoma, is a benign, slow-growing tumor that arises from the Schwann cells forming the sheath (covering) of the vestibulocochlear nerve. As the tumor grows, it expands from its origin inside the internal auditory canal out into the space between the brainstem and the bone known as the cerebellopontine angle. The pear-shaped tumor can continue to enlarge, compressing the trigeminal nerve, which is responsible for facial sensation. Eventually, the tumor can compress the brainstem. Acoustic neuromas are classified according to their size as small (less than 1.5 cm), medium (1.5 to 2.5 cm), or large (more than 2.5 cm) (Fig. 2).

What are the symptoms?

The symptoms caused by an acoustic neuroma follow the size and growth of the tumor. The most common first symptom is hearing loss in the affected ear, which often goes unrecognized or is mistaken for a normal change of aging. Small tumors, which are typically limited to the bony canal, cause hearing loss in one ear, tinnitus (ringing in the ears), and unsteadiness or dizziness. As the tumor expands, hearing loss may worsen, facial weakness may occur, and balance problems (disequilibrium) may occur. Large tumors can compress the brainstem (causing imbalance) and the trigeminal nerve (causing facial numbness). As brainstem compression becomes severe, the fourth ventricle collapses and hydrocephalus results, causing persistent headache and visual problems.

What are the causes?

The cause of acoustic neuromas is largely unknown. No environmental factor (such as cell phones or diet) has been scientifically proven to cause these tumors. Acoustic neuromas can be sporadic or caused by an inherited condition called neurofibromatosis type 2 (NF-2). Sporadic tumors occur 95% of the time, while 5% of acoustic neuromas occur with NF-2.

Neurofibromatosis is a rare disease that occurs in two forms. Type 1 causes tumors to grow on nerves throughout the body, especially the skin. Type 2 can cause acoustic neuromas on both the left and right sides, creating the possibility of complete deafness if the tumors grow unchecked. The presence of bilateral acoustic tumors affects the choice of treatment, as hearing preservation is a prime objective.

Who is affected?

Acoustic neuromas affect about 10 people in one million. More women than men are affected. Patients are usually diagnosed between 30 to 60 years of age.

How is a diagnosis made?

The doctor will ask about your personal and family medical history and will perform a complete physical examination. In addition to checking your general health, the doctor will perform a neurological exam. This will include checks for mental status and memory, cranial nerve function (sight, hearing, smell, tongue and facial movement), muscle strength, coordination, reflexes, and response to pain. Diagnostic tests may include:

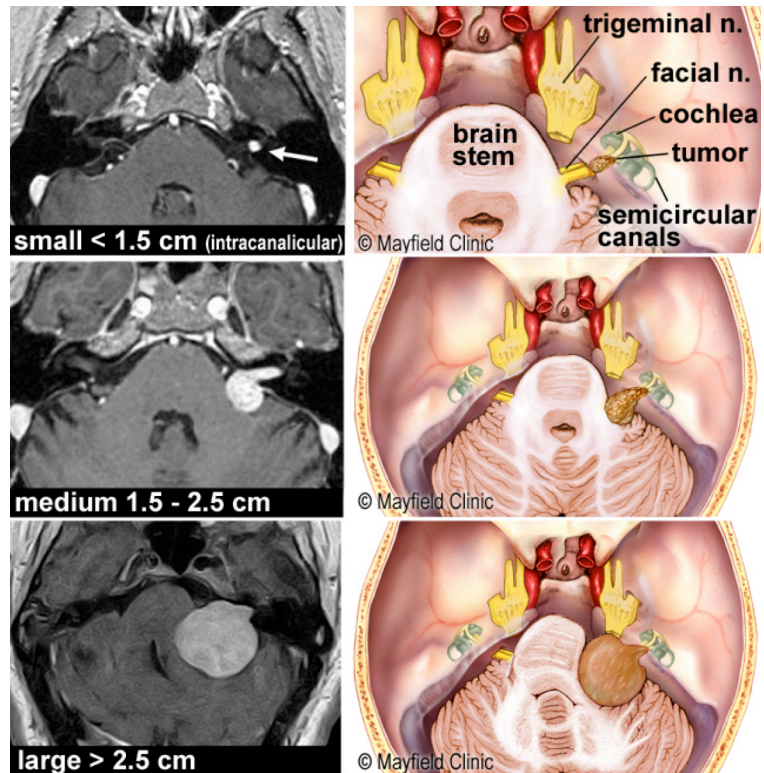


Figure 2. MRI scans of small, medium, and large sizes of acoustic neuromas.

Audiogram is a hearing test performed by an audiologist. During the test, you will wear earphones and hear a range of sounds at different tones directed to one ear at a time. Also, speech discrimination will be assessed. The test can detect whether you have hearing loss that is sensorineural (from nerve damage) or conductive (from eardrum or ossicle damage).

Electronystagmography (ENG) is a test that evaluates your balance by detecting eye movements while stressing your balance in various ways. During ENG, eye movements are recorded with small electrodes placed on the skin around the eyes. Alternatively, eye movements may be recorded by videonystagmography (VNG), using an infrared video camera mounted inside goggles that you wear.

Magnetic Resonance Imaging (MRI) is a test that uses a magnetic field and radiofrequency waves to give a detailed view of the soft tissues of the brain. A contrast dye called gadolinium may be injected into the bloodstream during scanning to make tumors more visible. MRI is useful in evaluating lesions and their effects on surrounding brain structures (Fig. 2).

Computed Tomography (CT) is a test that uses X-rays and a computer to view anatomical structures within the brain. It is especially useful for viewing changes in bony structures, such as widening of the internal auditory canal.

Auditory Brainstem Response (ABR) is a test that checks the hearing pathway to the brainstem. Electrodes on the scalp and earlobes capture the brain's responses to clicking noises heard through earphones.

What treatments are available?

The treatment that is right for you will depend on your age, general health, hearing status, and the tumor size. The larger the tumor, the more complex the treatment. Therefore, early recognition, diagnosis, and treatment are essential. Because patients and acoustic neuromas differ, it is important to seek treatment at a medical center that offers the full range of options, including surgery, radiosurgery, and hearing or facial rehabilitation. A neurosurgeon, otologic surgeon, and radiation oncologist work as a team to treat acoustic neuromas.

Observation (“watch and wait”)

Acoustic neuromas that are small and have few symptoms may be observed with MRI scans every year until tumor growth or symptoms change. The average acoustic neuroma growth rate is 0.66 to 1.5 mm per year. In 40% to 50% of observed patients, tumor growth or progression of symptoms will prompt the need for surgery or radiosurgery. Observation may be the best option for older patients with other health conditions or patients with a tumor in their only hearing ear.

Surgery

Surgical removal is a common treatment for acoustic neuromas, especially large ones. Priorities in surgery are: first, the maintenance of facial nerve function; second, the preservation of socially useful hearing in the affected ear; and third, complete tumor removal. While total tumor removal may result in a cure, it also carries a higher risk of hearing and facial nerve damage. During tumor removal, a probe is used to stimulate and monitor the nerves and brainstem function. Because acoustic tumors grow slowly, small remnants of tumor capsule may be left attached to critical nerves. Partial removal may be advocated to reduce the chances of facial nerve damage. If the tumor remnant grows, radiosurgery may be used.

There are several surgical approaches to opening the skull (craniotomy) and removing the tumor (Fig. 3). The choice of a particular approach depends on the tumor size, tumor position, and hearing status.

- **Suboccipital (retrosigmoid):** A craniotomy is made behind the ear in the occipital bone. Bone overlying the internal auditory canal is removed to expose and remove the tumor. This approach may be used for all tumor sizes, but especially large ones, while preserving facial nerve function and useful hearing if possible.
- **Middle fossa:** A craniotomy is made above the ear in the temporal bone. Bone overlying the internal auditory canal is removed to expose and remove the tumor. This approach may be used for small tumors and when preservation of hearing is optimal.

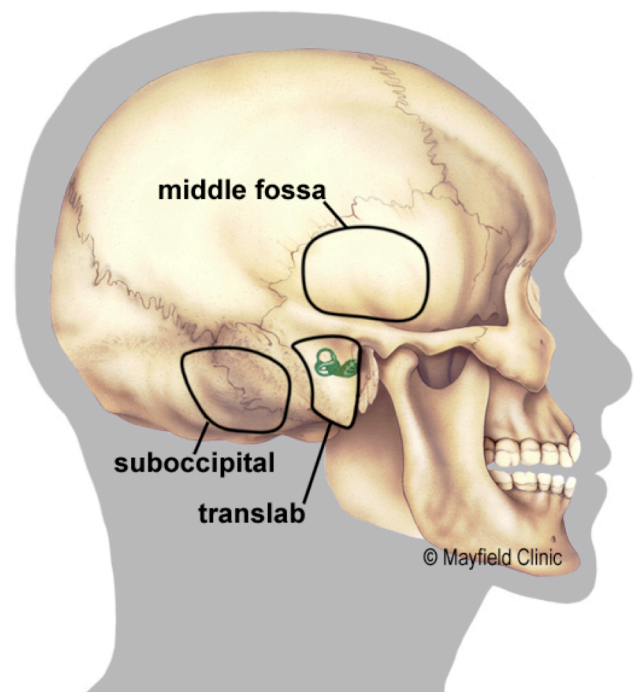


Figure 3. Three surgical approaches to an acoustic neuroma: middle fossa, suboccipital, and translabyrinthine.

- **Translabyrinthine:** A craniotomy is made through the ear in the mastoid bone. The semicircular canals are removed to expose the tumor in the internal auditory canal. Because the canals are removed, complete hearing loss occurs in the affected ear. This approach may be used for patients who already have hearing loss or when preservation of hearing is not possible.

Outcomes of surgery depend on the size and adherence of the tumor, the use of cranial nerve monitoring, and the skill of the surgical team. The medical literature reports vary, but overall, facial movement is preserved in more than 90% of patients, and useful hearing is preserved in 20-80%. Rates of success on postoperative hearing preservation and facial function are inversely related to tumor size. Delayed hearing loss may occur after surgery in 30-50% of patients who had useful hearing immediately after surgery. Partial-removal techniques have higher rates of hearing and facial function preservation immediately after surgery; however, a recent long-term study revealed that subtotal resection had a three-fold higher rate of tumor regrowth and no long-term impact on facial nerve function or hearing [8].

Complications of surgery may include facial weakness or paralysis, cerebrospinal fluid leak, persistent headache, meningitis, and stroke. Tumor recurrence is less than 5% after surgical removal.

Stereotactic Radiosurgery

The goal of radiosurgery is to stop or control tumor growth. It does not remove the tumor. Radiation is used to treat small and medium-sized acoustic neuromas (<2.5 cm). Using highly focused radiation beams, radiosurgery works by damaging the DNA inside cells and making them unable to divide and reproduce. The aim of radiation therapy is to maximize the dose to abnormal cells and minimize exposure to normal cells (Fig. 4). The benefits of radiation are not immediate but occur over time. Gradually, the tumor stops growing and may shrink in size. Periodic MRI scans are necessary to monitor for tumor changes.

The two main radiosurgery technologies are the Leksell Gamma Knife and linear accelerator systems, such as the BrainLab Novalis. A stereotactic frame or mask is attached to the patient's head to precisely localize the tumor on an MRI scan and to hold the head perfectly still during treatment. Highly focused beams of radiation are delivered to the acoustic neuroma over approximately one hour.

Published studies of radiosurgery for acoustic neuromas report 90-95% tumor control, 70% hearing preservation, a 1% risk of facial weakness, and a 3% risk of bothersome facial numbness [5].

Complications after radiation may include hearing loss, facial weakness, facial sensory loss, radiation necrosis, and brainstem injury. There is also a slight risk of radiation-induced malignant tumors years after treatment. Radiation can cause scar tissue to develop around the tumor and facial nerve, making surgical removal more difficult should the tumor grow back.

Clinical trials

Clinical trials are research studies in which new treatments—drugs, diagnostics, procedures, and other therapies—are tested in people to see if they are safe and effective. Research is always being conducted to improve the standard of medical care. Information about current clinical trials, including eligibility, protocol, and locations, are found on the web. Studies can be sponsored by the National Institutes of Health (see clinicaltrials.gov) as well as private industry and pharmaceutical companies (see www.centerwatch.com).

Recovery and prevention

Coping with the possibility of hearing loss and facial paralysis and deciding which treatment is best for you can be difficult. The Acoustic Neuroma Association collects and publishes outcomes data from member surveys on their website.

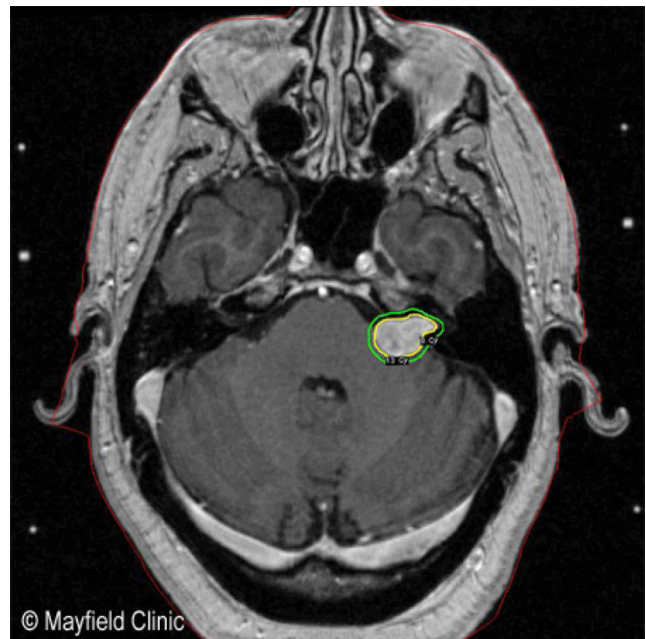


Figure 4. Radiation treatment plan for an acoustic neuroma. Colored lines around the tumor indicate radiation dose to the tissue.

Hearing preservation is an important goal for patients with an acoustic neuroma, although it is not always possible. All treatment options carry a risk of hearing loss. The Gardner-Robertson Scale is used to measure useful hearing (1=good, 2=serviceable) (Fig. 5). Hearing loss in one ear affects your ability to tell where a sound is coming from. An audiologist or speech therapist can help you learn tips for coping with one-sided deafness. Certain types of hearing aids called CROS (Contralateral Routing of Sound) and BAHA (Bone-Anchored Hearing Aid) may be helpful. These hearing aids take sound that would normally enter the non-hearing ear and route the signal to the hearing ear.

Patients with NF-2 can develop bilateral acoustic neuromas, and many may eventually lose hearing in both ears. All NF-2 patients with bilateral acoustic neuromas should learn sign language before deafness occurs. An auditory brainstem implant (ABI) can be inserted during surgery to provide a sensation of hearing by bypassing the cochlea and directly stimulating the brainstem. The

device does not enable the full range of hearing, but it does provide increased noise awareness. Most patients are able to hear noises, such as a ringing telephone, but the degree of hearing usefulness can vary greatly. An auditory brainstem implant, combined with lip reading, helps improve communication.

Balance problems can be improved with physical therapy, Pilates, or Tai Chi. Dizziness is common and will persist until the opposite ear is able to compensate and stabilize, usually within 1 to 4 months. Persistent problems with balance, dizziness, or vertigo may require treatment with vestibular rehabilitation.

Facial exercises and massage are recommended to improve facial nerve function. The House-Brackmann Scale is used to evaluate facial nerve function before and after treatment (Fig. 6). If a patient has facial weakness after treatment, eye care consists of artificial tears and lubricant until facial nerve function returns. If a patient has facial paralysis 1 year after surgery, the chance of further recovery is reduced. Consultation with an ENT surgeon who specializes in facial plastic and reconstructive surgery is recommended.

Acoustic neuromas sometimes recur after radiation or surgery. Periodic MRI scans (every 1 to 2 years) and hearing tests are important for long-term monitoring.

Sources & links

If you have questions, please contact Mayfield Brain & Spine at 800-325-7787 or 513-221-1100.

Support

Support groups are available through the Acoustic Neuroma Association; call 770-205-8211.

Links

- Acoustic Neuroma Association www.anausa.org
- Children’s Neurofibromatosis Foundation www.ctf.org
- American Hearing Research Foundation www.american-hearing.org

Gardner-Robertson Hearing Scale

Grade	PTA (dB)	SD (%)
I: Good	0-30	70-100
II: Serviceable	31-50	50-69
III: Non-serviceable	51-90	5-49
IV: Poor	90-100	1-4
V: Deaf	0	0

PTA = pure tone average
SD = speech discrimination score

Figure 5. The Gardner-Robertson hearing scale. Grades I and II are considered "useful hearing" (able to hear a phone conversation).

House-Brackmann Facial Weakness Scale

- I: Normal symmetrical function in all areas.
- II: Slight weakness; Complete eye closure with minimal effort; Slight asymmetry of smile; Synkinesis barely noticeable, contracture, or spasm absent.
- III: Obvious weakness, but not disfiguring; May not be able to lift eyebrow; Complete eye closure and strong but asymmetrical mouth movement; Obvious, but not disfiguring synkinesis, mass movement or spasm.
- IV: Obvious disfiguring weakness; Inability to lift brow; Incomplete eye closure and asymmetry of mouth; Severe synkinesis, mass movement, spasm.
- V: Motion barely perceptible; Incomplete eye closure, slight movement corner mouth; Synkinesis, contracture, and spasm usually absent.
- VI: No movement, loss of tone, no synkinesis, contracture, or spasm.

Figure 6. The House-Brackmann facial weakness scale. Grades I and II are considered socially acceptable facial function.

Sources

1. Bakkouri WE, et al. Conservative management of 386 cases of unilateral vestibular schwannoma: tumor growth and consequences for treatment. *J Neurosurg* 110:662-669, 2009
2. Raftopoulos C, et al. Microsurgical results with large vestibular schwannomas with preservation of facial and cochlear nerve function as primary aim. *Acta Neurochir* 147:697-706, 2005
3. Samii M, et al. Hearing Preservation after Complete Microsurgical Removal in Vestibular Schwannomas. Régis J, Roche P-H (eds): *Modern Management of Acoustic Neuroma*. *Prog Neurol Surg* 21:136-141, 2008
4. Tamura M et al. Hearing preservation after gamma knife radiosurgery for vestibular schwannomas presenting with high-level hearing. *Neurosurgery* 64:289-96, 2009
5. Flickinger JC. Hearing Preservation up to 3 Years After Gamma Knife Radiosurgery for Gardner-Robertson Class I Patients With Vestibular Schwannomas. *Neurosurgery* 76:584-591, 2015
6. Carlson ML, et al. Long-term quality of life in patients with vestibular schwannoma: an international multicenter cross-sectional study comparing microsurgery, stereotactic radiosurgery, observation, and nontumor controls. *J Neurosurg* 122:833-842, 2015
7. Whitmore RG, et al. Decision analysis of treatment options for vestibular schwannoma. *J Neurosurg* 114(2):400-13, 2011
8. Monfared A, et al. Facial Nerve Outcome and Tumor Control Rate as a Function of Degree of Resection in Treatment of Large Acoustic Neuromas: Preliminary Report of the Acoustic Neuroma Subtotal Resection Study. *Neurosurgery* 79:194-203, 2016

Glossary

- acoustic nerve:** the eighth cranial nerve, also known as the vestibulocochlear nerve, is responsible for hearing and balance.
- brainstem:** connects the upper brain to the spinal cord; responsible for autonomic functions such as breathing and heart rate.
- cerebellopontine angle:** the space between the cerebellum and pons of the brainstem and the petrous bone.
- cerebrospinal fluid (CSF):** a watery fluid that flows within the ventricles and around the surface of the brain and spinal cord.
- craniotomy:** a surgical opening in the skull.
- disequilibrium:** a lack of balance caused by a problem in the vestibular system of the ear.
- facial nerve:** the seventh cranial nerve, responsible for movement of the face.
- facial palsy:** paralysis of the facial muscles on one side.
- neuroma:** tumor originating from nerve cells; also called neurinoma, schwannoma.
- neurofibromatosis:** an inherited condition that causes tumors to grow on nerves throughout the body. Type 1 (NF-1) tumors grow on or below the skin and in the peripheral nerves. Type 2 (NF-2) tumors grow on spinal and cranial nerves and can cause bilateral acoustic neuromas. Also called von Recklinghausen disease.
- radiation necrosis:** death of healthy tissue caused by delivery of radiation to kill tumor cells.
- tinnitus:** ringing or buzzing noise in the ear.
- vertigo:** a feeling of spinning, whirling or turning.



updated > 4.2018

reviewed by > Vincent DiNapoli, MD, PhD, Ronald Warnick, MD, Mayfield Clinic, Cincinnati, Ohio

Mayfield Certified Health Info materials are written and developed by the Mayfield Clinic. We comply with the HONcode standard for trustworthy health information. This information is not intended to replace the medical advice of your health care provider. © Mayfield Clinic 1998-2018.